

# *Eye Problems in General*

Phattharaphong Tantichariyangkul, MD, FICO



MED NU 2023: UNEASY SITUATION FOR GENERAL PHYSICIAN





	SV	PALs	Degressive	Blue/UV coating	Coating	Photochromic	Sunglasses	Reduce Myopic Progression	Technology	Individualised Fitting
ESSILOR	EYEZEN start (antifatique, dualoptim) EYEZEN boost/plus (initial0.4/active0.4)	Varlux X series (Xclusive4D/Xclusive) Varlux E series (Easy-to-wear) Varlux S series (Nanoptix balance „Sy) Varlux Physio 3.0 Varlux Comfort Max (Flex Optim) SV Roadpilot II SV Exceptio (-40 to +30 or beyond)	Varlux Digitime (near80/mid100/room) Varlux Computer 3V (large int) Varlux Computer 2V (int and near) Interview80/130 (large near)	Crizal Sapphire 360 UV Crizal Provencia Crizal Rock Crizal Alize UV Crizal Easy UV	Opifog (antiglare & fog both sides) Antifog AR (antiglare front & antifog b	Transitions Signature GENB Transitions XTRActive Polarized (activ Transitions Vantage (variable polarizat Transitions Drivewear (polarized)	Xperio Sun Xperio Polarised Xperio Mirror Crizal Sun XProtect (Ionic shield strengthen	Stellest (HALT) MyoPiLux SightGlass (DOT)	WAVE & WAVE 2.0 (wavefront advanc Path Optimizer Binocularbooster Flexoptim Nanoptix (anti off-balance) Synchroneyes (calculate both lenses as a pair for smooth far-near refraction) Xtend (extend sharp vision area within arm-length 16-28" or 60-85% add power with ED DualOptix	Eyecode (with Visiooffice automatic device) Fit (frame) AWA (customise 0.01 D scale) 4D (dominant eye fast saccade) NVB (ipad, near visual behaviour) DualOptix
HOYA	Nulux Identity V+ SYNC III (antifatique) Nulux Trueform (freeform) Hilux Trueform Nulux Hilux Sportive SV EnRoutePro SV (Driving) Nulux Seamless Aspheric (Aptakia)	Hoyalux ID MySelf Hoyalux ID MyStyle V+ (Trueview I) Hoyalux ID LifeStyle 3/3 Hoyalux ID Balansis (integrated double surface FF) Daynamic (full back surface PAL) Amplitude Trueform Amplitude EnRoutePro Progressive(Driving) Sportive Progressive	Hoyalux ID WorkStyleV+ 200,400 Tact200,400 Addpower80 (60cm)	UV control Blue control UV block385/400	Hi-Vision LongLife Super Hi-Vision Hi-Vision Aqua Hi-Vision Aqua Concave Glare filter	Sensity Sensity Dark Sensity Shine		MIYOSMART+ (DIMS)		Trueview i / Lite automatic device
NIKON	SEEMAX Infinite (freeform 8 axis, talk MyopSee (DAS) RELAXEE Neo (antifatique) Lite AS	SEEMAX Ultimate SEEMAX Master SEEMAX Power Presio Master Presio Power Presio W	SOLTES Wide Neo Home&Office Neo DigLife	Pure blue UV pro Pure blue UV SEECOAT Next Blue SEECOAT Blue UV SEECOAT plus UV	SEEEOAT Bright/Next Bright (Augme) SEEEOAT Drive SEEEOAT Next	Transitions XTRActive	Sunstyle Polarshade (polarize)			
ZEISS	SV Sph SV AS (mineral/plastic/Tri SV Superb + Asia SV Individual (with Digital Lens (antif DriveSafe Individual DriveSafe SV EnergizeMe SV (CL user, antifatique, EnergizeME Digital (0.65D)	Individua/balan Fusion Plus Individual (individual Digital Lens (antif DriveSafe PAL DriveSafe PAL EnergizeMe PAL (+0.75-4.00 D) EnergizeME Digital (0.65D)								
RODENSTOCK	Perfallt (Sph) Cosmolit (AS) Perfallt Mono Plus 2 (antifatique) Perfallt Mono Sport 2 (high wrap) Multigressiv Mono2 + Plus (Back multi Impression Mono2 + Plus (Back multi Impression Mono Sport2	Progressiv Life Free2 Progressiv PureLift Free2 B.I.G. Multigressiv MyView Impression2 Impression Freesign3	Progressiv Ergo2 Book/PC/Room Multigressiv Ergo2 Book/PC/Room Impression Ergo2 Book/PC/Room Impression Ergo2 G2 Myxema (color veisians)		X-tra Clean Solitaire Protect Plus2	ColorMatic IQ2				Impression ST DrEye
TOKAI										

I HAVE NO  
CONFLICT OF INTERESTS  
IN THE PRESENTATION



# Ophthalmology Subspecialties

Low vision  
& Rehabilitation

Ped-Oph  
& Strabismologist

Uveitis

Retina

Ocular  
Pathologist

Neuro-Oph

Oculoplastic

Cornea &  
Refractive Sx

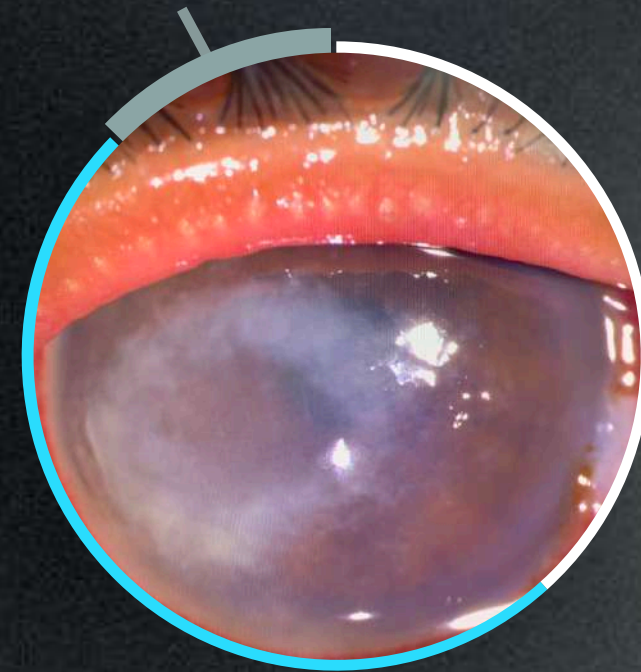
Glaucoma



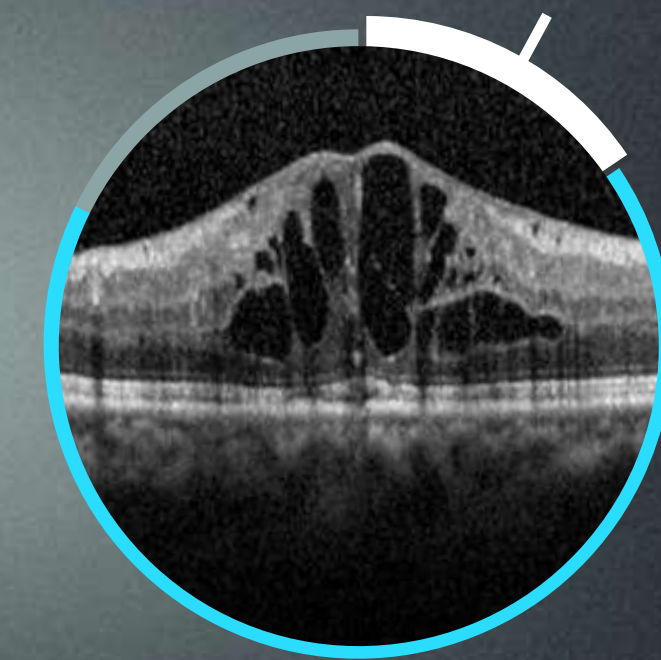


# WHAT are common PRESENTATIONS of EYE PROBLEMS?

Ocular Pain & Discomfort



Others: Appearance, Screening

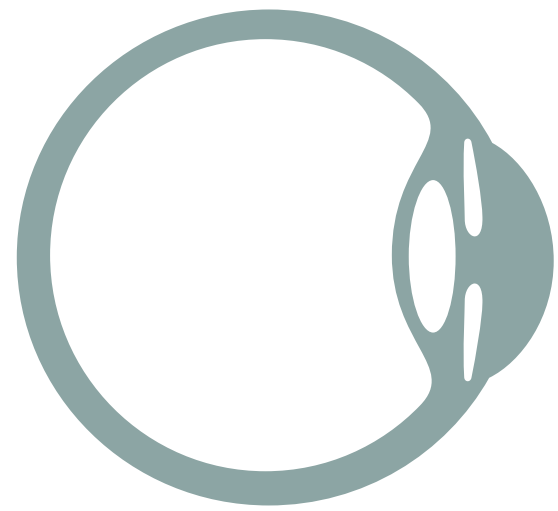


Visual Symptoms





# Modalities of Visual Functions



Visual Acuity

Visual Field

Contrast Sensitivity

Color (Ishihara, Fransworth, Red pin)

RAPD (Anterior visual pathway)

Binocular vision (Diplopia, Stereoacuity)

Refractive Error (Defocus)

ERG, VEP, EOG



Image Resolution

Image/Canvas Size

Contrast + Resolution

Hue & Saturation

Exposure/Brightness between 2 images

Merge images > Ghost images, etc

Blur or Sharpen tool

Calibrate for Dead pixel



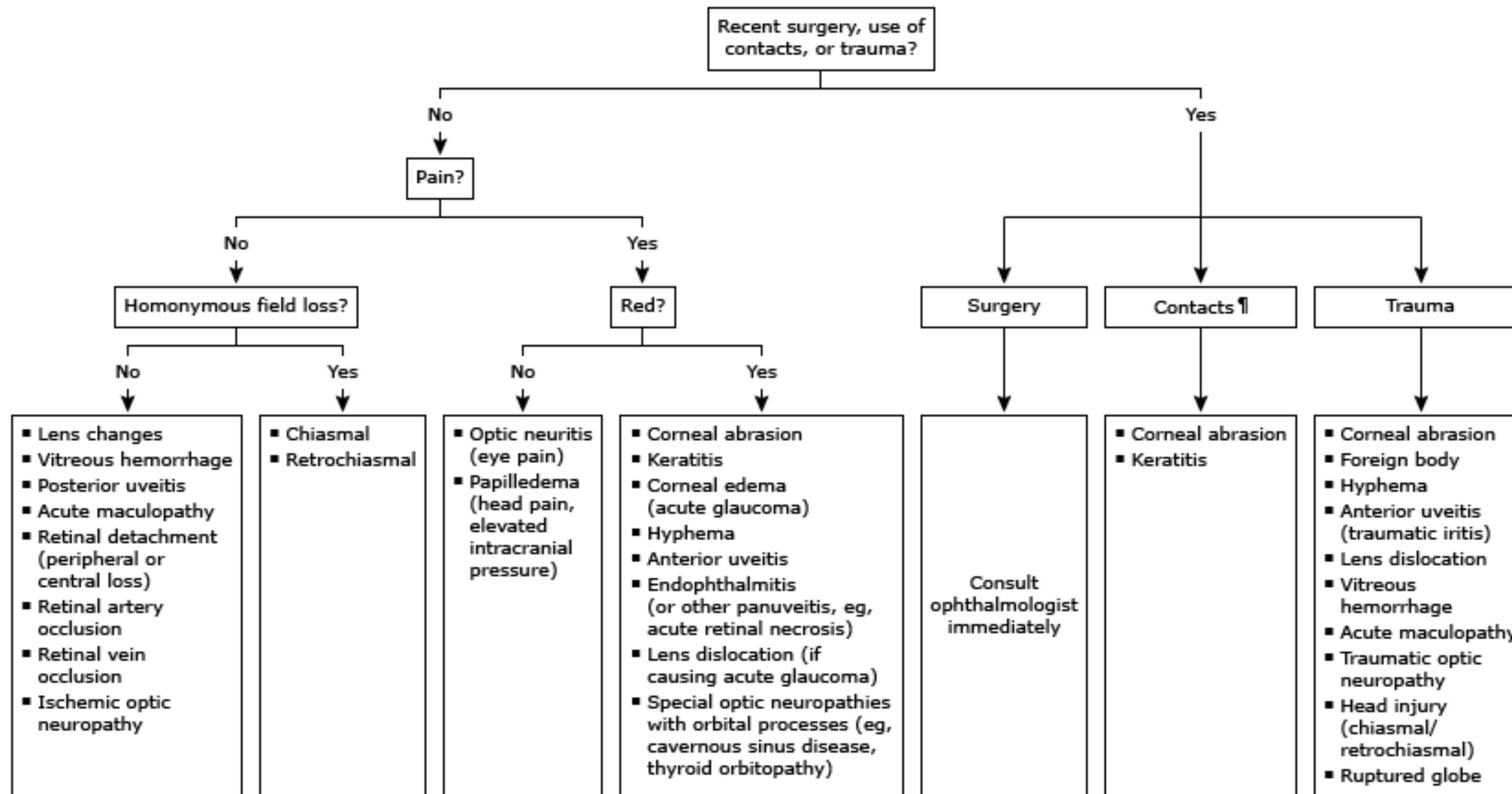
# Approaching Ocular Problems



**OUTSIDE IN**



# Approaching Visual Problems





# Approaching Visual Problems

Refractive Error	Media Opacity	Retina & Choroid	Neural Visual Pathway
Hyperopia	Ptosis	Vasculopathies DR CRAO CRVO Leukemia Hyperviscosity	Pre-chiasmal lesions from ganglion cell layer (GCL)
Myopia	Discharge, Tear film instability	Retinal detachment	Optic neuropathies; glaucomatous ischemia, inflammatory, infectious
Astigmatism	Cornea; keratitis, scar edema (glaucoma), dystrophy	Maculopathy / Choroidopathy eg. AMD, PCV, CSC, Drug-induced	Disc swelling / Papilledema
Others eg. Higher order aberrations (HOA)	Anterior chamber: hyphema (spontaneous or traumatic), uveitis	Retinitis Infection / Inflammation	Chiasmal lesions Pituitary, Craniopharyngioma
Ocular misalignment eg. Strabismus	Cataract	Neoplasm	Post-chiasmal lesions Brain lesions eg. stroke, mass, PRES
	Vitreous hemorrhage Vitritis, Floaters	Dystrophies eg. Retinitis pigmentosa	Visual Aura, Migraine



# Approaching Visual Problems



## Hx Taking

LODCRAFT

PHx FHx

Trauma/Sx

Prior Tx



## Refraction

Pinhole

Spectacles

Contact lens

Day/Night Vision



## Eye Exam

Lid, Lash, Conjunctiva,  
Tear film, Cornea, A/C, Iris,  
Lens, Vitreous, Retina, Optic  
nerve, Chiasm, Tract, LGB  
to visual cortex, CN III, IV, VI





# Approaching Visual Problems

## Cataract RE

### Hx Taking

70 yr old  
Blurry + glare RE  
progressed for 6 months  
No other symptoms

### Refraction

VA RE 20/100 PH 20/70  
VA LE 20/40 PH 20/25  
Non-significant refractive error

### Eye Exam

Conjunctiva, Cornea, A/C WNL  
Lens: NS + CC  
Fundus: WNL





# Approaching Visual Problems

## Dry Eyes from Meibomian Gland Dysfunction

### Hx Taking

Generalized blurry BE  
off and on for years  
Worse: outdoor/working  
Improve with blink

### Refraction

VA - 20/25<sup>+1</sup>  
VA c PH - 20/20<sup>-1</sup>  
Unstable refraction  
(astigmatism)

### Eye Exam

Lid margin: meibum plugs  
Conj: mildly injected  
Tear film instability  
Cornea: epith. erosions





# Approaching Visual Problems

## Posterior Vitreous Detachment (PVD) RE

### Hx Taking

Floater/flashing RE  
for months  
Worse: lateral gaze

### Refraction

VA 20/20  
Emmetropia

### Eye Exam

Anterior segment: WNL  
Vitreous floaters  
Lattice degeneration





# Approaching Visual Problems

PVD RE, High Risk Retinal Break > Laser Retinopexy

Hx Taking

Floater/flashing RE  
for months  
Hx of laser LE  
Hx of head trauma

Refraction

VA 20/20  
High Myopia

Eye Exam

Anterior segment: WNL  
Vitreous floaters  
Lattice degeneration





# Approaching Visual Problems

VH RE, Suspicious of PVD or Retinal Break

## Hx Taking

Floater/flashing RE  
for months  
Full of floaters today  
Last checkup: no U/D

## Refraction

VA 20/20<sup>-2</sup>  
Emmetropia

## Eye Exam

Anterior segment: WNL  
Vitreous hemorrhage gr I-II  
Normal background fundus





# Approaching Visual Problems

RRD, Macula on > Emergency retina repair Sx

## Hx Taking

Floater/flashing RE  
for months  
Blurry inferior (1 dPTA)  
to central vision today

## Refraction

VA 20/100 PH 20/70<sup>-2</sup>  
VA LE 20/20  
Hx prior RE vision = LE

## Eye Exam

Anterior segment: WNL  
Superior RRD, macula on  
(involve superior macula)





# Approaching Visual Problems

VH RE, Suspicious of PDR > Consult

## Hx Taking

Blurry RE for years  
Floaters for days  
Can't see anything today  
Last visit: 1st Dx DM

## Refraction

VA RE HM, LE 20/40  
Auto-Refracton: RE  
unable, LE emmetropia

## Eye Exam

Anterior segment: WNL  
Except pupil SRTL BE  
RE Vitreous hemorrhage gr IV  
(Cannot evaluate fundus)





# Approaching Visual Problems

## Migraine with Visual aura (Scintillating scotoma)

### Hx Taking

Headache after seeing zigzag dancing light followed by blurry image, expand to 50% of visual field in both eyes, lasting 30 min

### Refraction

VA 20/20  
(no symptom now)  
Emmetropia

### Eye Exam

WNL





# Approaching Visual Problems

Acute Angle Closure RE > IOP lowering agent & LPI

Hx Taking

At 4 AM

Headache N/V 4 hrs

RE blurry & see halo

around lightings

Refraction

VA 20/70

Auto-Refraction: unable

Eye Exam

Tense globe

Ciliary injection

Slightly cloudy cornea

Mid-dilated fixed pupil





# Approaching Visual Problems

## Optic Neuritis RE

### Hx Taking

Headache for 4 day  
Blurry RE with  
Color desaturation

### Refraction

VA RE 20/100 PH NI  
VA LE 20/20

### Eye Exam

Anterior segment: WNL  
Except RAPD RE  
no disc swelling RE  
Ishihara RE 6/24, LE 24/24



# Approaching Visual Problems

Bilat. Optic Neuritis, Suspicious of NMOSD/AntiMOG

## Hx Taking

Headache for 1 day  
Blurry RE > LE with  
Color desaturation

## Refraction

VA RE 20/400 PH NI  
VA LE 20/50 PH NI

## Eye Exam

Anterior segment: WNL  
Except RAPD RE  
Mild disc swelling RE  
Ishihara RE 0/24, LE 0/24





# Approaching Visual Problems

Advance glaucoma RE > LE

## Hx Taking

70 yr old  
Blurry + dark vision RE  
progressed for 6 months  
No other symptoms

## Refraction

VA RE 20/20  
VA LE 20/20  
Emmetropia

## Eye Exam

IOP RE 28 LE 25  
Anterior segment: WNL  
Except RAPD RE  
C:D RE 0.9 LE 0.7





# Approaching Visual Problems

Rt Post-chiasmatic lesion, Suspicious of Stroke

## Hx Taking

75 yr old, Sudden  
painless blurry vision BE  
U/D Old CVA, HT, DM  
Hx Cataract Sx BE 10 yr

## Refraction

VA RE 20/25 PH 20/20  
VA LE 20/25 PH 20/20  
Nearly emmetropia

## Eye Exam

Anterior segment: WNL  
RAPD negative  
Normal fundus  
Confrontation: Lt hemianopia





# Approaching Visual Problems

## Asthenopia, Presbyopia

### Hx Taking

37 yr old  
Intermittent blurry vision  
periocular dull-aching pain  
worsen during E-sport

### Refraction

VA RE 20/20  
VA LE 20/20  
Hyperopia +1 BE

### Eye Exam

WNL





# Approaching Visual Problems

## Monocular Diplopia from Refractive Error

### Hx Taking

80 yr old  
Diplopia 2 months  
Cannot drive his car  
U/D: HT DM DLP

### Refraction

VA cc RE 20/50 PH 20/25  
VA cc LE 20/70 PH 20/30  
Hyperopic astigmatism

### Eye Exam

Anterior segment WNL  
Normal fundus examination  
EOM full auctions & versions  
APCT orthophoria





# Approaching Visual Problems

## Bilateral Sixth Nerve Palsies > Workup

### Hx Taking

80 yr old  
Diplopia 1 day  
Cannot drive his car  
U/D: HT DM DLP

### Refraction

VA (BE open) 20/20  
without diplopia  
both Snellen & near chart  
Emmetropia

### Eye Exam

Anterior segment WNL  
Normal fundus examination  
EOM limit abduction 80 PD BE  
APCT ET 30 PD on side gazes





# Approaching Visual Problems

Divergence Insufficiency > Prism spectacles

## Hx Taking

80 yr old  
Diplopia 1 day  
Cannot drive his car  
Last checkup: no U/D

## Refraction

VA (BE open) 20/20  
without diplopia  
both Snellen & near chart  
Emmetropia

## Eye Exam

Anterior segment WNL  
Normal fundus examination  
EOM full ductions & versions  
APCT: ET 10 PD, ortho at near



# Approaching Red Eye & Discomfort



**OUTSIDE IN**



# Approaching Red Eye & Discomfort

## Lid & Lashes

Cellulitis / Panophthalmitis

Hordeolum / Chalazion / Neoplasm

Meibomian Gland Dysfunction

Thyroid orbitopathy

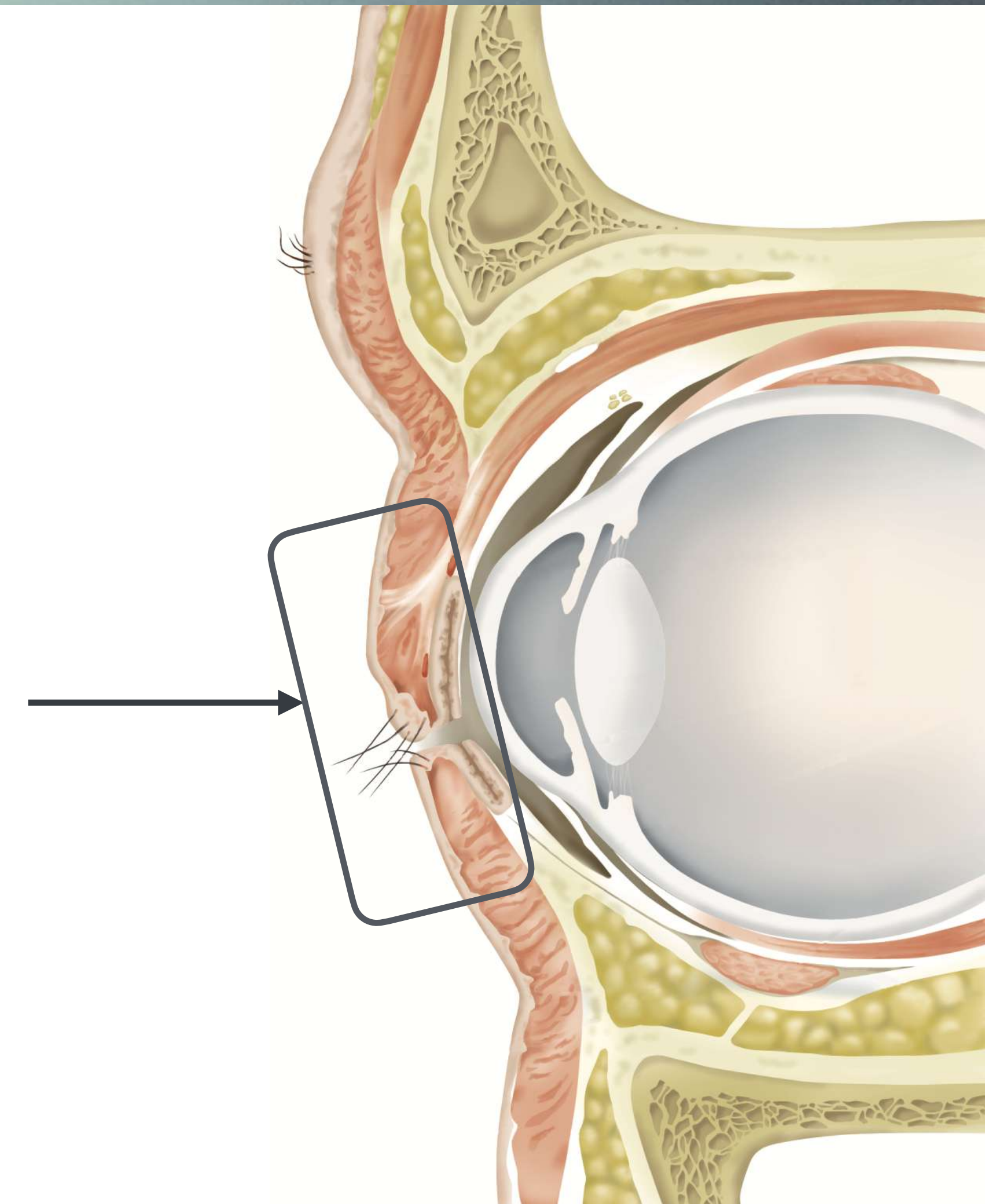
Herpes Simplex / Zoster Blepharitis

Trichiasis / Distichiasis

Ectropion / Entropion / Epiblepharon

Blepharospasm / Hemifacial spasm

Dacryocystitis / Canaliculitis

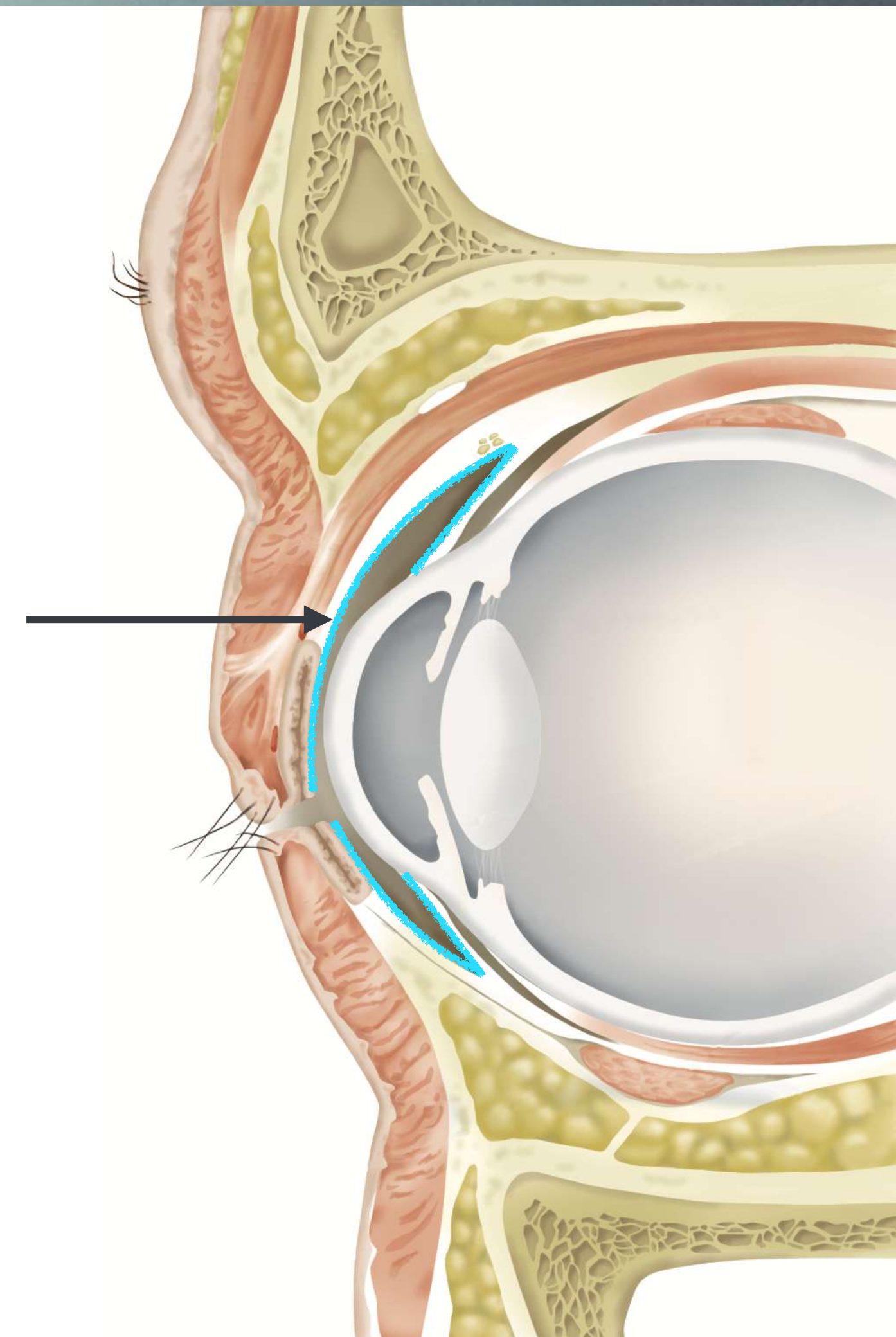




# Approaching Red Eye & Discomfort

## Conjunctiva

Conjunctivitis / Episcleritis  
Infection: Viral, Bacterial, Parasitic  
Inflammation / SJS / Allergic  
Masquerade / Neoplasm  
Thyroid orbitopathy  
Subconjunctival Hemorrhage  
Foreign body / Lithiasis

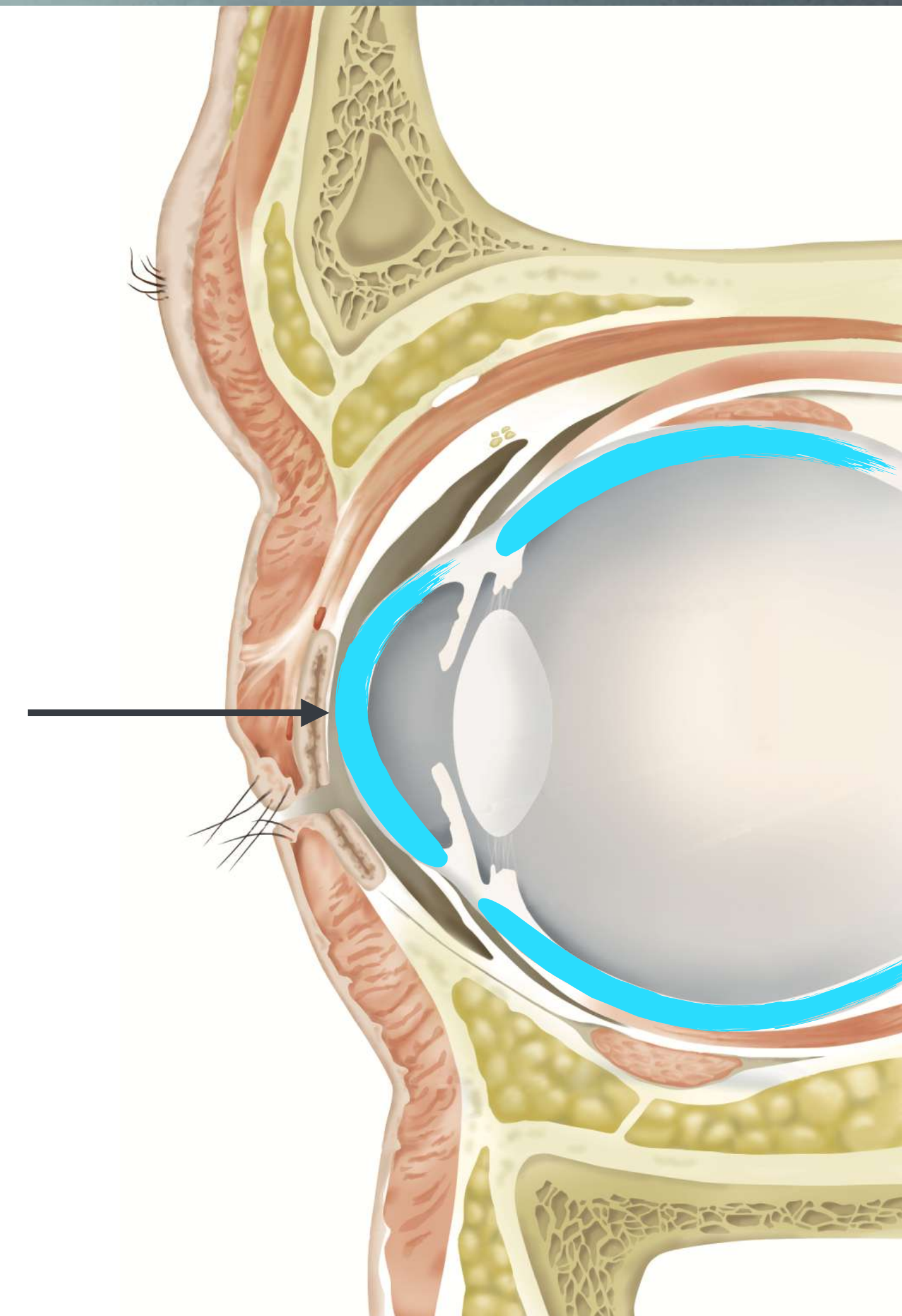




# Approaching Red Eye & Discomfort

## Tear film Cornea & Sclera

- Dry Eyes
- Epithelial defect / Abrasion
- Contact lens overwear
- Scleritis / Keratitis
- Infection / Inflammation
- Foreign body / Neoplasm





# Approaching Red Eye & Discomfort

## A/C - Iris - Lens Ciliary body

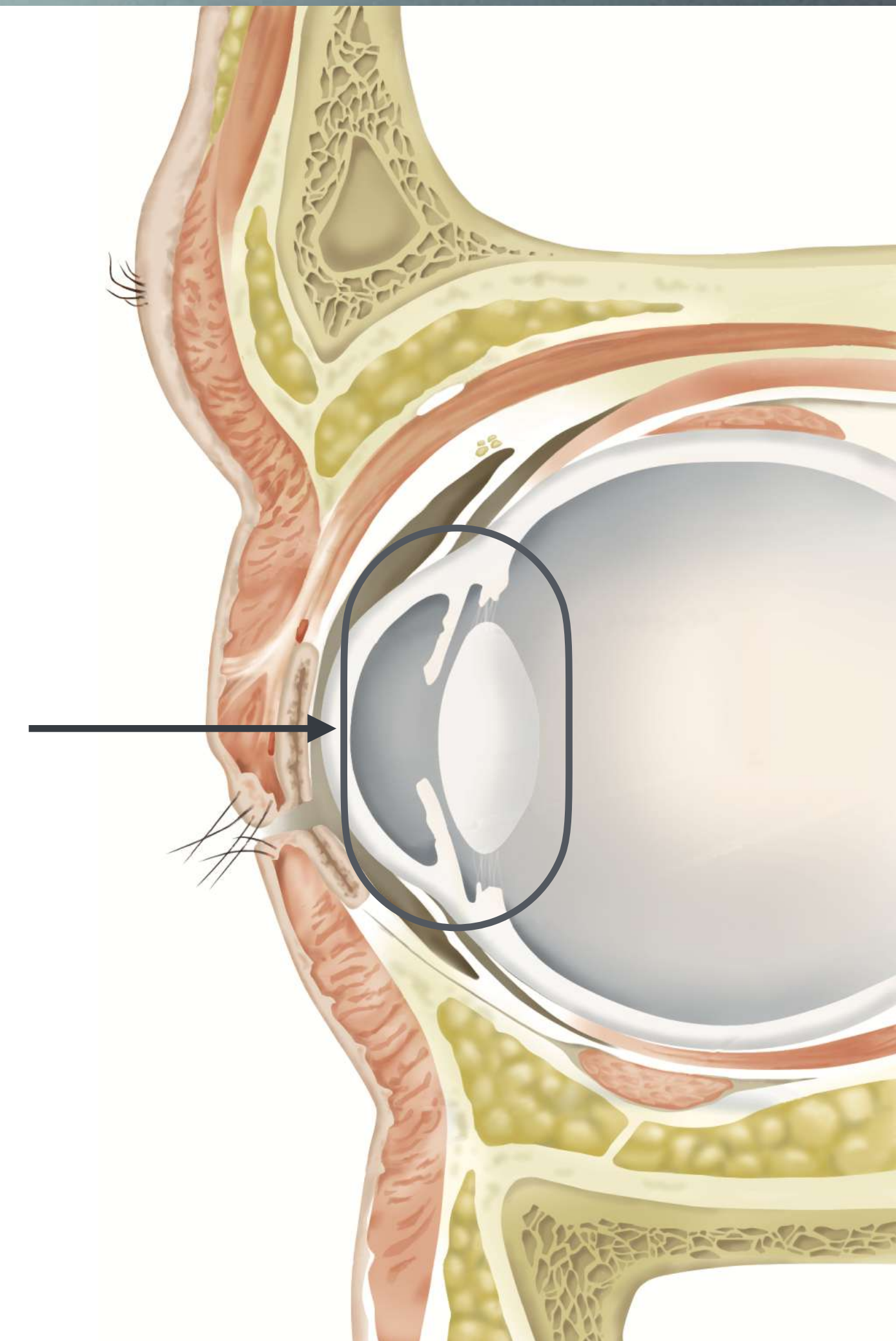
Anterior uveitis (Iritis, Iridocyclitis, Cyclitis)

Angle closure (Primary / Lens-induced)

HypHEMA / Hypopyon

eg. Endophthalmitis

Masquerade

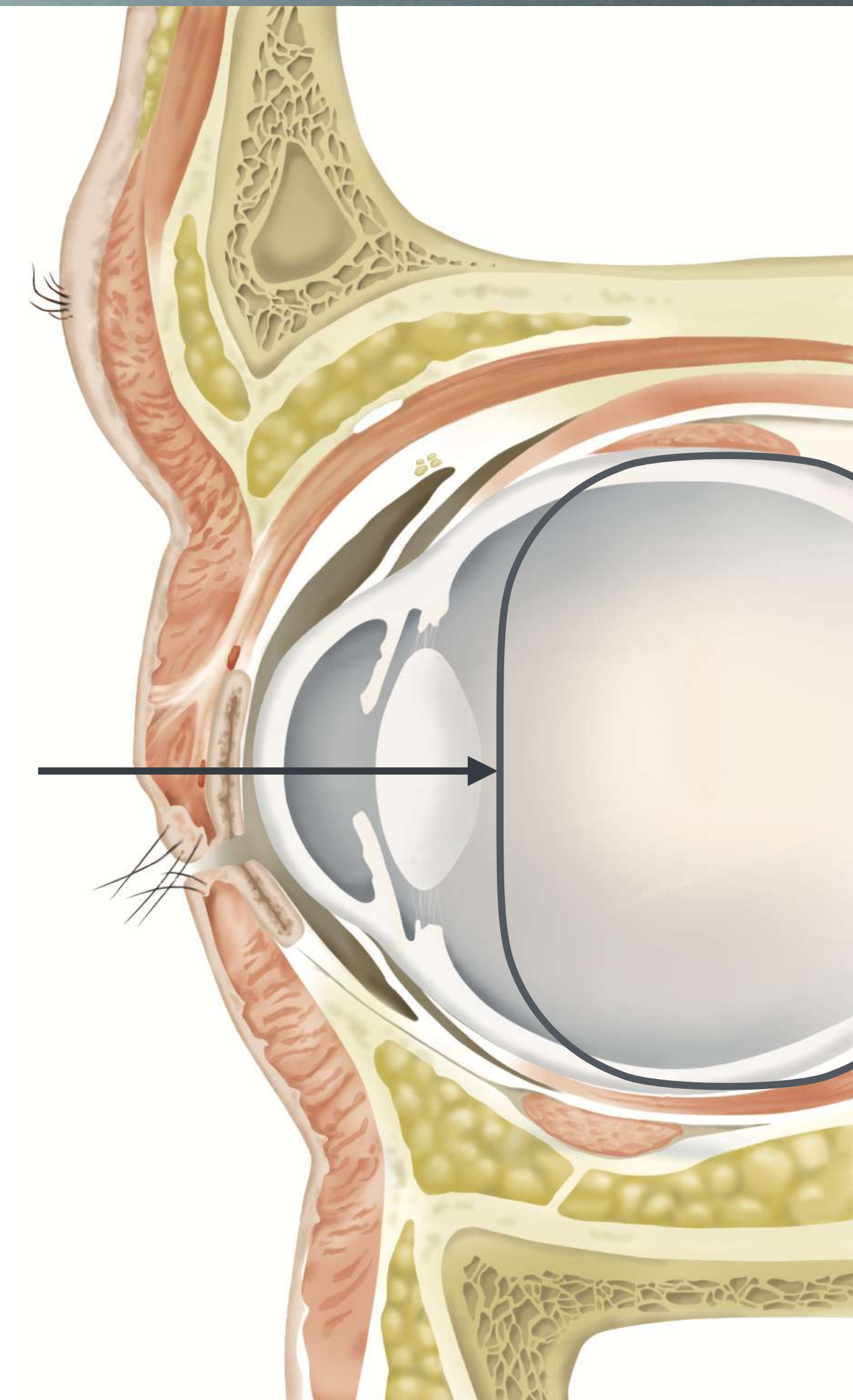




# Approaching Red Eye & Discomfort

## Posterior Segment

- Vitritis / Endophthalmitis
- Panophthalmitis
- Posterior Scleritis
- Retrobulbar Optic Neuritis

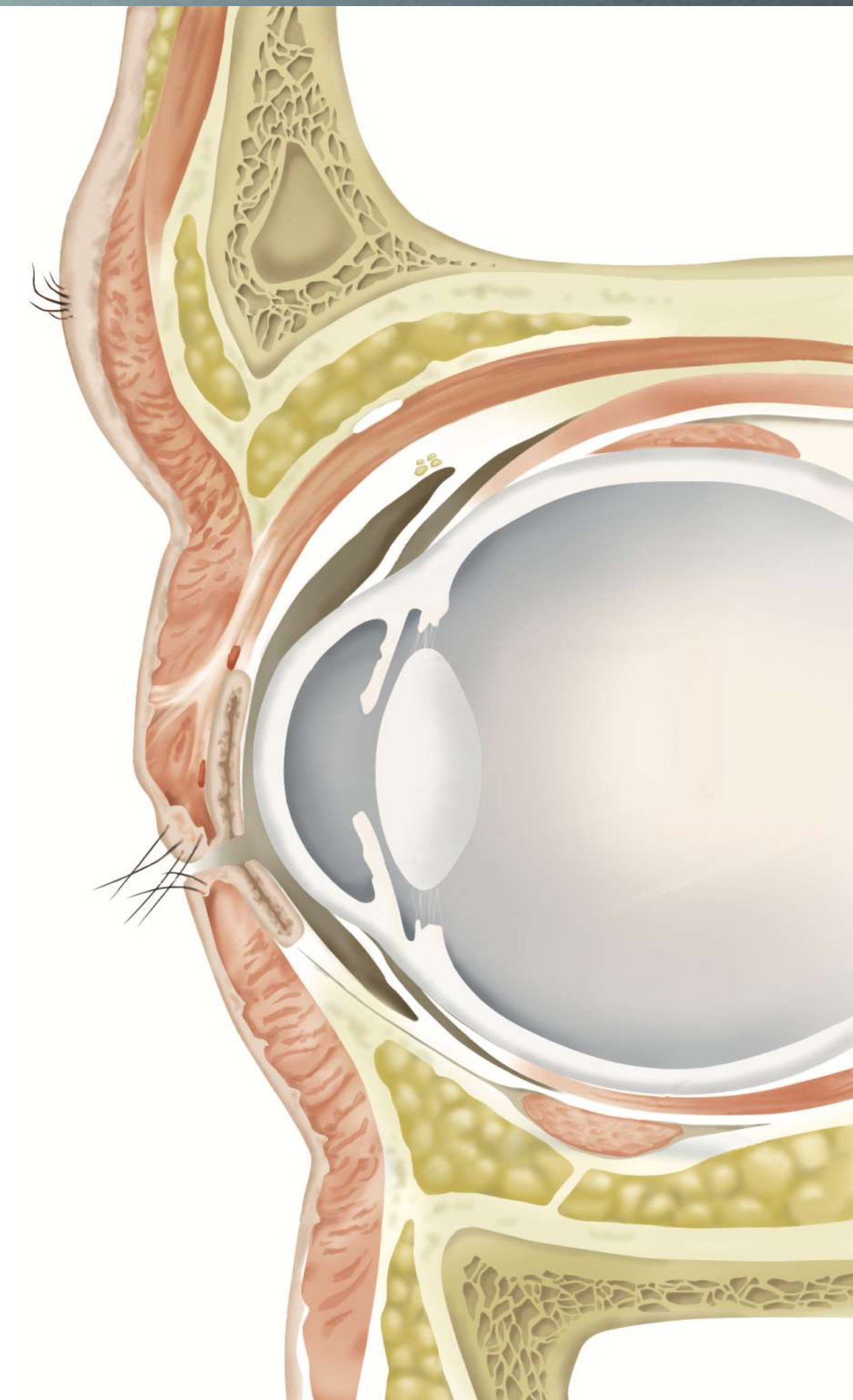




# Approaching Red Eye & Discomfort

## Asthenopia (Fatigue)

- Excessive near work
- Hyperopia
- Presbyopia
- Overcorrection of Myopia
- Spasm of near reflex
- Strabismus eg. X(T) maintain fusion





# Eye Screening

## Non-specific

For general patients

Walk in / screening package

Visual functions (VA, Refraction, Colour), IOP  
Comprehensive eye exam (may not dilate pupil)

## Specific

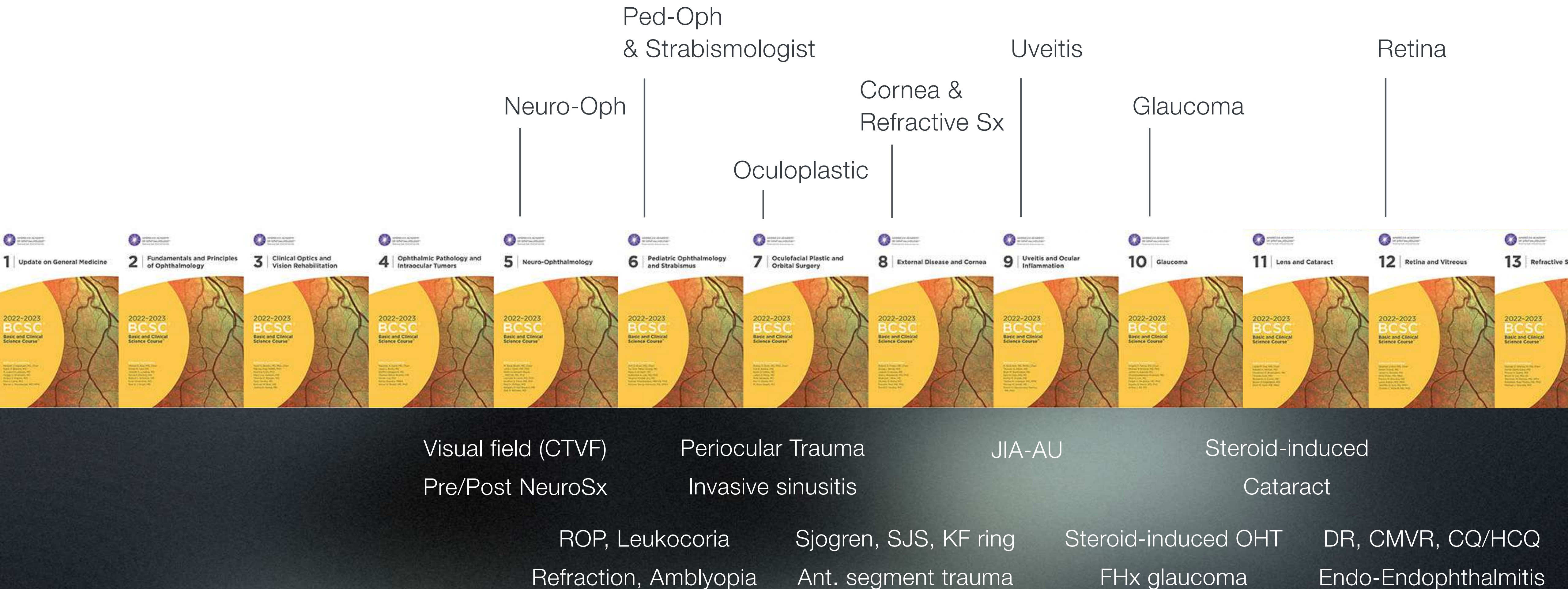
For increased risk patients

By consultation

Eg. DR, CMVR, HCQ/CQ Maculopathy,  
Endogenous endophthalmitis, ROP



# Common Specific Screening







# TAKE HOME MESSAGE

Hx Taking: LODCRAFT, PH, FHx, Trauma/Sx, Prior Tx

Outside-in Approach: VA cc/pinhole, ant -> post -> visual pathway

Photograph: obtained with patient consent, very useful





THANKS FOR  
YOUR ATTENTION